

FULL PAPER

Effect of platelet rich fibrin (PRF) and hydroxyapatite from eggshells to TGF β and ALP in the healing of rat bone defects

Mujaddid Idulhaq^{a,*} | Pamudji Utomo^b | Ambar Mudigdo^c | Brian Wasita^c^aDoctoral Program, Faculty of Medicine, Universitas Sebelas Maret, Surakarta, Indonesia^bDepartment of Orthopaedic & Traumatology, Faculty of Medicine Sebelas Maret University, Prof Dr R. Soeharso Orthopaedic Hospital Surakarta^cDepartment of Anatomical Pathology, Dr. Moewardi Hospital/Faculty of Medicine UNS, Surakarta, Indonesia

Biomaterials, such as hydroxyapatite and platelet-rich fibrin (PRF), are increasingly used in orthopedic treatments due to their beneficial properties. Hydroxyapatite offers osteoconduction, osteointegration, and osteoinduction, while PRF expedites bone healing. This study aims to assess the impact of hydroxyapatite derived from eggshells and PRF on bone healing in Wistar rats. A post-test only control group experimental study was conducted on Wistar rats, divided into five groups: normal (N), control (K), hydroxyapatite-filled bone defect (P1), PRF (P2), and PRF-hydroxyapatite (P3). The subjects underwent immunohistochemical analysis of bone healing biomarkers, including TGF β and ALP. Mean expressions of each variable were compared using One-Way ANOVA. Hydroxyapatite and PRF significantly increased ALP expression ($P < 0.05$). TGF β expression increased with PRF and hydroxyapatite, although not statistically significant ($P > 0.05$). The combination of PRF and hydroxyapatite from eggshells can enhance the bone healing process in rat models with bone defects.

***Corresponding Author:**

Mujaddid Idulhaq

E-mail: mjd.orto@gmail.com

Tel.: +628122265862

KEYWORDSBone defect; PRF; hydroxyapatite; TGF β ; ALP.**Introduction**

Bone defects are a condition that is often found in orthopedic surgery practice, and is still a challenge in its management in orthopedic clinical practice. In America, more than 500,000 bone grafts have been performed on the defect bone due to trauma, tumor, degeneration, and other diseases in the field of orthopedics and traumatology [1]. In Indonesia, based on data from the Dr. Soetomo Hospital, Surabaya 62 orthopedic biomaterials were used in 2010, 75 in 2011 and 178 in 2012 [2]. Meanwhile, data from Prof Dr R Soeharso Orthopedic Hospital showed 500 synthetic graft preparations are

needed for bone replacement in patients during 2020. Bone grafts are the primary method of treating bone abnormalities because they are expected to supply osteogenesis, osteoinductive, and osteoconductive components, which are essential for bone healing. As a gold standard in the treatment of bone defects is the use of bone grafts, namely the type of autograft (from the individual), but has the disadvantage of being limited in number, causing deformity and pain at the donor site. Furthermore, the other types are allograft (from the same species but different individuals) and xenograft (from different species) [3].

Another management strategy is to manufacture synthetic bone substitutes. Materials which have the basic element calcium which can be made into bio-materials in the form of hydroxyapatite (HA) are being developed more and more, due to their beneficial biological properties, which include biocompatibility, bioaffinity, bioactivity, osteoconduction, osteointegration, and osteoinduction (under certain conditions) [4,5]. Another strategy is the addition of materials containing growth factors, one of which is Platelet-rich fibrin (PRF) which is suspected to accelerate healing in bone conditions with bone defects. The TGF- β growth factor contained in PRF can stimulate the formation of mesenchymal stem cells (MSC). TGF- β is also said to be able to stimulate Wnt activity, and then Wnt will bind to β -catenin in cells which is a protein in the pathway main process of osteogenesis. Therefore, MSC will differentiate into osteoblasts as the main cells that play a role in the process of bone regeneration. The increase in osteoblast activity will increase bone protein markers such as alkaline phosphatase (ALP) and osteocalcin (OCN) [1,6].

Based on the data from the Directorate General of Livestock in 2023, egg production in 2022 amounted to 6,339,890 tons. An estimated 10% of this becomes eggshell waste, meaning 633,989 tons of eggshells are discarded as waste each year [7]. Eggshells themselves contain 94% calcium carbonate, 1% potassium phosphate, and 1% magnesium carbonate [8], making them a significant potential source for hydroxyapatite. This is accompanied by an increasing demand for synthetic hydroxyapatite, especially for orthopedic surgeries, and the high cost of commercial hydroxyapatite, making the potential utilization of eggshell-derived hydroxyapatite a solution to existing problems [9]. Several investigators have used PRF in combination with HA, or the

other agents for the treatment of bone defects. However, the HA used is a synthetic material, not from egg shells. There is no similar study that uses a combination of hydroxyapatite from eggshells and PRF.

Therefore, it is hypothesized that the combination of hydroxyapatite from eggshells and PRF will yield better results in bone regeneration in particularly for the treatment of bone defects using rat models, as indicated by an increased expression of TGF β and ALP. The objective of this study is to evaluate the influence of combination of hydroxyapatite obtained from eggshells and PRF on the process of bone healing for the treatment of bone defects in Wistar rats.

Materials and methods

The present study employed an experimental research methodology that utilized a post-test only control group design with the utilization of Wistar rats as experimental subjects. The study was conducted from October 2021 to December 2022. The male Wistar rats utilized in this research were between the ages of 8-12 weeks and had a weight range of 450-600 grams. The sample size consisted of 25 subjects, which were divided into five distinct groups: normal (N), control (K), and subjects treated solely with EHA (P1), PRF (P2), or a combination of PRF and EHA (P3).

Platelet rich fibrin

Two mL of venous blood was taken from the tail vein of the rats used in the experiment into a regular tube without the addition of anticoagulant and immediately centrifuged at room temperature by laboratory centrifugation for 10 minutes at 3000 rpm. In the center of the tube, a PRF clot will form between the supernatant acellular plasma and the lower red blood cells. The PRF clot is removed using sterile clamps that are applied to the created bony defect [1].

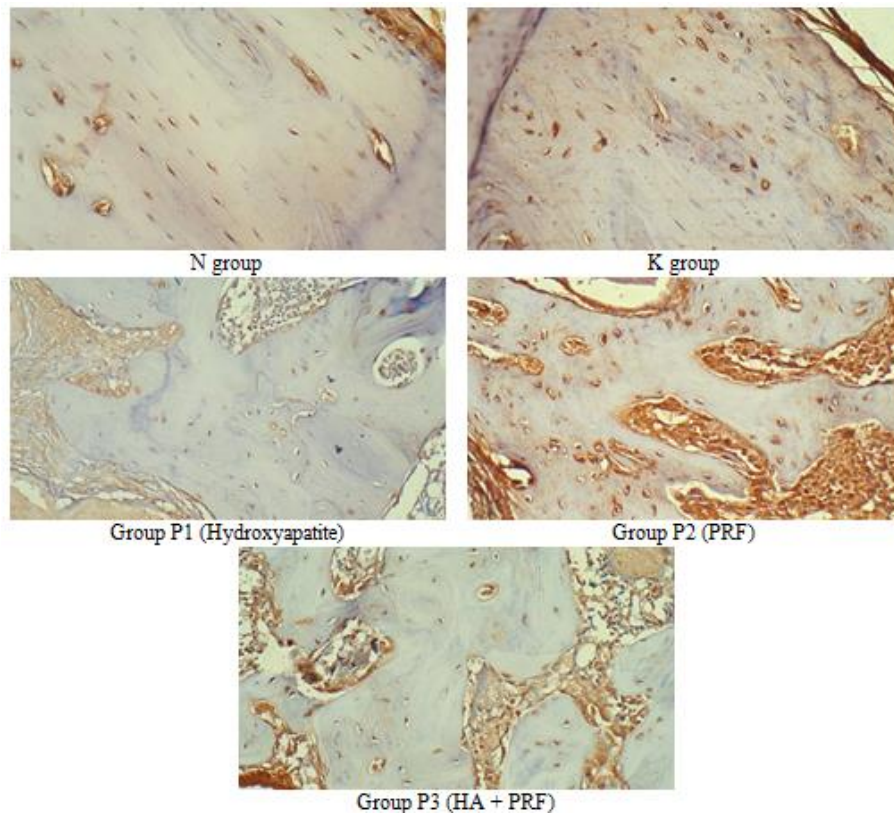


FIGURE 1 TGF- β immunohistochemical results using 100x magnification in each group

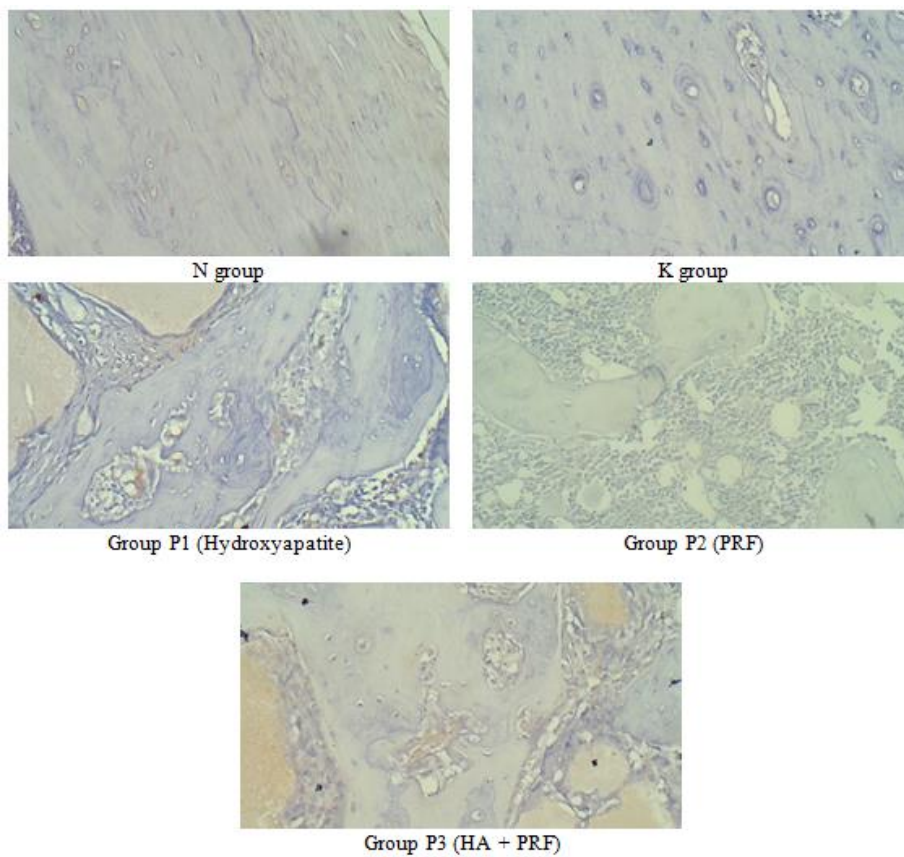


FIGURE 2 ALP immunohistochemistry results using 100x magnification in each group

Hydroxyapatite from eggshells (Eggshell HA)

The chicken egg shells, upon being rid of dirt and membranes, underwent a drying process within an oven set at 110 °C for 2 hours. The dried eggshells were then crushed using a ball mill, and then sieved (standard Tyler sieve) to obtain eggshell powder with a pass size of 50 mesh. The eggshell powder was then calcined in a furnace (Nabertherm model L 9/11/SKM) at 1000 °C for 5 hours to produce white calcium powder [10]. The process of HA synthesis was executed through the gradual addition of 100 mL of phosphate solution into the calcium solution. The heating was fixed at a constant temperature of 40 °C, whilst the agitation speed was set at 300 rpm. Following the completion of the reaction of phosphate solution, stirring was continued for an additional 30 minutes without any heating. Following the lapse of this timeframe, the precipitation process was conducted for 24 hours. The precipitate was subjected to filtration via Whatman 42 filter paper and subsequently rinsed with aquabides to eliminate residual ammonium nitrate. The desiccation of the precipitate was conducted at 110 °C for 2 hours to eradicate any outstanding aquabides that may have been introduced during the washing process. The resultant dried precipitate was subjected to sintering at 1000 °C for 5 hours [10].

Bone defects

In this particular study, the bone defects were observed in experimental animals, specifically adult male Wistar rats aged 8-12 weeks and weighing between 450 and 600 grams. Male rats were chosen to avoid conditions of hormonal changes, for example: pregnancy which can occur in female rats, so that population uniformity is obtained [3]. Surgery was performed with antiseptic action, under anesthesia, an incision was made on the lateral side of the

right femur, critical bone defects were made on the distal right femur bone with a diameter and depth of 1 cm in all rats. The volume of the hole is approximately 3.14 cubic centimeters. The rats were divided into 5 groups, where the first group served as normal controls (N), namely rats that were left untreated for normal data (baseline). The second group is the control rat (K), which is after the defect is left empty without anything being filled. The third group (P1) where the bone defect was filled with hydroxyapatite from the egg shell according to the volume of the defect, around 3 cm³, the fourth group (P2) the defect was filled with PRF, and finally the last group (P3), the defect was filled with PRF and hydroxyapatite with a ratio of 1 : 1 fulfills the defect volume. After completing the treatment, the skin was closed with stitches. The rats were treated and observed by being given a standard diet, and then terminated on the 28th day. It was expected that the osteogenesis process has entered the stage until the formation of new bone on the 28th day [11,12].

Evaluation of Immunohistochemistry

Evaluation of IHC results was observed using an Olympus CX22 Microscope in the Department of Anatomical Pathology by an Anatomical Pathologist. All 25 samples were observed for accumulated total expression of: TGF β polyclonal antibody (pAb) from Abclonal and anti-ALPL antibody from FineTest®. Stained cells (immunoreactive) were counted for their total accumulation in the entire field of view using a magnification of 400x. Subsequently, the total percentage was calculated to be used as the percentage of protein expression of TGF β and ALP.

Statistical analysis

In this study, the data obtained was statistically analyzed using the Statistical

Product and Service Solutions (SPSS) program for Microsoft Windows release 25.0. The number of research samples was less than 50 samples, so the Shapiro-Wilk distribution test was used to determine the distribution of TGF β and ALP. The statistical test used was the one-way ANOVA test to compare 5 unpaired sample groups with normal distribution. If the data was not normally distributed, the Kruskal-Wallis test was used [13].

Results

Post-test histological tissue collection was carried out after the sample was made of femur bone defects, given research treatment according to each group, and observed for 28 days. The sample tissue was then taken to the Laboratory of Anatomical Pathology to be examined by immunohistochemistry and histomorphometry for the variables studied. All the results are presented in Table 1. The immunohistochemical staining are presented in Figures 1 and 2.

The results of immunohistochemical examination of TGF- β and ALP were expressed as a percentage. The mean value of TGF- β in the normal group (N) was 3.02 ± 1.87 and in the control group (K) was

6.76 ± 4.24 . While the average number of TGF- β in the sample group treated with EHA (P1), PRF (P2), and PRF with EHA (P3), respectively were 5.57 ± 4.23 , 10.53 ± 10.65 , and 10.16 ± 5.95 . The results of the Kruskal Wallis test showed that there were no differences between TGF- β groups ($P = 0.349$, $P > 0.05$). The mean ALP score in the normal group (N) was 0.32 ± 0.66 and in the control group (K) was 0.19 ± 0.25 . While the average number of ALP in the EHA treatment sample group (P1), PRF (P2), and PRF with EHA (P3) were 0.50 ± 0.24 , 0.22 ± 0.21 , and 1.20 ± 0.51 respectively. The results of the Kruskal Wallis test showed that there were no differences between ALP groups ($P = 0.01$, $P < 0.05$).

The Mann-Whitney Post Hoc analysis was utilized to examine the differences in ALP among various groups. Upon conducting the Mann-Whitney Post Hoc analysis, it was discovered that there were significant differences in outcomes between group N and group P3, group K and group P3, group P1 and group P2, group P1 and group P3, as well as group P2 and group P3. These outcomes provided evidence that the administration of EHA with PRF had a significant impact on elevating ALP in comparison to all other groups. All post hoc analysis is indicated in Table 2.

TABLE 1 The mean percentage of the results of the immunohistochemical variable

Variable	Group	N	Mean + Standard Deviation (%)	P-value
TGF- β	N	5	3.02 ± 1.87	0.349 ^a
	K	5	6.76 ± 4.24	
	P1	5	5.57 ± 4.23	
	P2	5	10.53 ± 10.65	
	P3	5	10.16 ± 5.95	
ALP	N	5	0.32 ± 0.66	0.01 ^{a*}
	K	5	0.19 ± 0.25	
	P1	5	0.50 ± 0.24	
	P2	5	0.22 ± 0.21	
	P3	5	1.20 ± 0.51	

Table legend: Group N: normal (N); Group K: control (K); Group P1: EHA (P1); Group P2: PRF (P2); Group P3: combination of PRF and EHA (P3); ^a Kruskal Wallis test (numeric data not normally distributed); *significant at $\alpha = 5\%$, $p < 0.05$.

TABLE 2 Results of post hoc Mann-Whitney analysis of ALP data

	Group	P-value
ALP percentage	Group N vs. Group K	0.401
	Group N vs. Group P1	0.115
	Group N vs. Group P2	0.399
	Group N vs. Group P3	0.047*
	Group K vs. group P1	0.056
	Group K vs. Group P2	0.674
	Group K vs. Group P3	0.009*
	Group P1 vs. Group P2	0.046*
	Group P1 vs. Group P3	0.028*
	Group P2 and Group P3	0.009*

Table legend: Group N: normal (N); Group K: control (K); Group P1: EHA (P1); Group P2: PRF (P2); Group P3: combination of PRF and EHA (P3); *significant at $\alpha = 5\%$, $p < 0.05$.

Discussion

The present investigation has revealed that the outcomes of TGF- β manifested no significant difference among the groups ($P > 0.05$). However, it was observed that the TGF- β level was 3.02 ± 1.87 in the normal group (N), which doubled in the control group (K) to 6.76 ± 4.24 , and exhibited a three-fold increase in the PRF and EHA group (P3) to 10.16 ± 5.95 . Nevertheless, this value did not attain statistical significance. These findings suggested that the experimental subjects experienced a physiological response that caused an elevation in TGF- β . The results presented in this study are consistent with existing theories that highlight the crucial role of TGF- β in the proliferation and differentiation processes involved in bone development and remodeling.

This is achieved through the TGF- β action in controlling osteoblast proliferation and remodeling, in addition to its influence on the synthesis of other growth factors such as VEGF. The reinstatement and restoration of microvascular and microcirculation, which are responsible for the provision of essential oxygen and nutrients to the fracture area, are crucial components of the bone healing process [6]. Moreover, the PRF and EHA (P3) group also showed an increase in TGF- β expression three times the normal state,

although this did not show statistical significance, this result is also in accordance with existing theory where the main growth factor in PRF is TGF- β , in this case TGF- β promoting new bone formation by stimulating the synthesis of collagen and fibronectin [14]. The results of this study were almost the same as those of Setiawatie *et al.*, administration of EHA increased TGF- β expression by up to two times, although not statistically significant [15].

The results of this study had indicated that there exist statistically significant differences in ALP expression between groups subsequent to the administration of PRF and HA ($P < 0.05$). These findings were in line with the results of the meta-analysis conducted by Idulhaq *et al.* (2022), which found that PRF interventions in combination with other materials were more effective than PRF alone. It is widely known that administering PRF has a positive impact on the wound healing process, particularly on angiogenesis [16]. According to Alhasyimi *et al.* (2018), the administration of carbonated hydroxyapatite and advanced Platelet Rich fibrin led to an increase in ALP expression in cases of orthodontic relapse on days 0, 3, 7, 14, and 21, as was observed. Hydroxyapatite is believed to enhance the immediate concentration of calcium and phosphate ions,

which are required for bone formation, while platelet-rich fibrin is believed to contain effective growth factors for the differentiation of osteoblast cells marked by alkaline phosphatase [17]. Platelet-rich fibrin contains elevated levels of growth factors that have a crucial function in hemostasis and bone healing processes. These growth factors include VEGF, PDGF, IGF, EGF, and TGF. The regulated release of these growth factors eventually stimulates osteogenesis via osteoconduction, osteoinduction, and angiogenesis. The VEGF content in PRF can drive osteocyte differentiation, migration, and accumulation while simultaneously enhancing ALP activity, which is consistent with the current study's findings. Previous *in vitro* studies have shown that PRF can influence osteoblast proliferation and boost ALP activity [17]. The 3-dimensional model of the PRF fibrin matrix plays an important role in tissue repair, fibrin acts as a *biological scaffolding material* as a site for cell attachment in the tissue healing process. Fibrin also carries the right amount of *growth factors* that ensure bioactivity processes occur properly during the healing period [18].

Although the findings are different from those of some existing studies, some studies have shown that PRF enhances the regeneration of bone formation when administered concomitantly with autogenous bone grafts [19]. This may be due to PRF exerting a more sustained effect, ensuring a slow and sustained release [20]. The release of these growth factors is essential to produce a synergistic effect, namely the maximum bone regeneration when given together with autogenous bone graft [21] as well as bone graft xenografts [22]. Meanwhile, hydroxyapatite (HA) is extensively employed in clinical settings and has been documented as a biocompatible and osteoconductive bone substitute material. Its inherent ability to establish a conducive milieu facilitates the recruitment and proliferation of

osteoprogenitor cells [23]. Hydroxyapatite has demonstrated a notable capacity for promoting bone regeneration. This beneficial effect is achieved without eliciting any inflammatory response, osteofibrosis or osteonecrosis, which are commonly observed in alternative bone graft substitutes [24]. There were various limitations to this study. For example, the termination time was carried out solely on the 28th day without verifying the acute process results. A better option was to start at the beginning, examining from the seventh, fourteenth, and twenty-first days. The researcher believes that if the immunohistochemistry results were repeated serially/several times, both during the acute process and thereafter, the results would reveal how each variable evolves from the first time it was treated till after. This might result in data analysis results that reveal more subtle distinctions. Another significant limitation was the small size of the specimens used in the study. The researcher acknowledges that a larger sample size would provide more robust and significant findings. Therefore, it is advisable for future research to consider using data from a larger sample size to strengthen our findings. Lastly, the use of relatively small experimental animals, namely rat, accompanied by small defects, creates complexity for pathologists in the field of anatomical pathology to assess the study outcomes. It would be better to use larger experimental animal such as sheep or cow to evaluate bone healing mechanism within the bone tissue. Despite these limitations, the writer remains confident that our research provides valuable insights into bone healing in rats.

Conclusion

There was an increase in ALP expression on administration platelet rich fibrin and hydroxyapatite from egg shells which were statistically significant in the healing process

of rats in bone defect models. In addition, the administration of platelet rich fibrin and hydroxyapatite derived from egg shells had also been linked to an increase in the expression of TGF β , although this increase was not found to be statistically significant in the aforementioned rat models. This showed there was an enhancement of bone healing using the combination of hydroxyapatite from egg shells and PRF for the treatment of bone defects in Wistar rats. There are several suggestions for forthcoming research. First, it is advisable to perform termination and sampling gradually, specifically on the 7th day, 14th day, 21st day, and 28th day, allowing the comprehensive observation of the influence of each variable. Second, it is recommended to use a more adequate sample size in the future. Finally, it is advisable to utilize larger animal models for easier examination of defects, enabling comprehensive evaluations through radiological adjuncts that better describe the bone healing mechanisms in the subjects.

Acknowledgments

The author would like to thank all staff of the Orthopedic Traumatology Specialist Medical Education Program, Department of Anatomical Pathology, Faculty of Medicine, Sebelas Maret University, Surakarta, and all parties who have helped complete this article.

Conflict of interest

The authors declare that they have no conflict of interest in this study.

Funding

The authors received no funding from any entity for the work they submitted.

Ethical Approval

This study obtained ethical approval from the Research Ethics Commission of the Faculty of Veterinary Medicine, Gadjah Mada University (Number 00015/EC-FKH/ Ex./2021).

Authors' Contributions

Each author contributed substantially to the production of this work on their own. MI: wrote and analyzed the data analysis, performed statistical analysis, and performed the surgeries; PU: conceptualized and reviewed the articles; AM: drafted and reviewed the article and contributed to the intellectual concept of the study; BW: wrote the article, contributed to the intellectual concept of the study and the entire research project.

Orcid:

Mujaddid Idulhaq:

<https://orcid.org/0000-0003-0895-248X>

Pamudji Utomo:

<https://orcid.org/0000-0001-6701-9521>

Ambar Mudigdo:

<https://orcid.org/0000-0002-3498-5106>

Brian Wasita:

<https://orcid.org/0000-0002-5501-3541>

References

- [1] (a) D. Rady, R. Mubarak, R.A.A. Moneim, Healing capacity of bone marrow mesenchymal stem cells versus platelet-rich fibrin in tibial bone defects of albino rats: an in vivo study, *F1000Research*, **2018**, 7. [[Crossref](#)], [[Google Scholar](#)], [[Publisher](#)], (b) N. Kalani, S.R. Mousavi, K. Eghbal, A. Kazeminezhad, Fifteen Pearls in treating lumbar disk herniation: A Narrative study, *Eurasian Journal of Science and Technology*, **2023**, 3, 55-66. [[Crossref](#)], [[Pdf](#)], [[Publisher](#)], (c) A.M. Milani Fard, M. Milani Fard, Evaluation of office stones in kidney patients and how to form and treat them, *Eurasian Journal of Science and Technology*, **2022**, 2, 111-125. [[Crossref](#)], [[Pdf](#)], [[Publisher](#)], (d) A. Amini, H. Shahpoori Arani, M. Milani Fard, Medical tourism industry: A systematic review on its principles, sequels, and ethical issues, *Eurasian Journal of Science and Technology*, **2022**, 3, 139-151. [[Crossref](#)],

- [Pdf], [Publisher], (e) S. El Baakili, A. Semlali, K. El Mabrouk, M. Bricha, Synthesis method effect on acellular bioactivity of bioglasses: structural analysis and solid-state NMR, *Journal of Applied Organometallic Chemistry*, **2023**, *3*, 268-283. [Crossref], [Pdf], [Publisher], (f) H. Shayegan, V. Safari Fard, H. Taherkhani, M.A. Rezvani, Efficient removal of cobalt(II) ion from aqueous solution using amide-functionalized metal-organic framework, *Journal of Applied Organometallic Chemistry*, **2022**, *2*, 109-118. [Crossref], [Pdf], [Publisher]
- [2] T.W. Martanto, R.V. Munthe, H. Suroto, S. Bayusentono, A.R. Hidayat, F. Mahyudin, The evaluation of chip freeze-dried cancellous bone allograft of local products usage as a scaffold in completing small defects on long bone, *EurAsian Journal of BioSciences*, **2020**, *14*, 3415-3418. [Google Scholar], [Publisher]
- [3] Y. Li, S.K. Chen, L. Li, L. Qin, X.L. Wang, Y.X. Lai, Bone defect animal models for testing efficacy of bone substitute biomaterials, *Journal of orthopaedic translation*, **2015**, *3*, 95-104. [Crossref], [Google Scholar], [Publisher]
- [4] V.S. Kattimani, P.S. Chakravarthi, N.R. Kanumuru, V.V. Subbarao, A. Sidharthan, T.S. Kumar, L.K. Prasad, Eggshell derived hydroxyapatite as bone graft substitute in the healing of maxillary cystic bone defects: a preliminary report, *Journal of international oral health: JIOH*, **2014**, *6*, 15-19. [Pdf], [Google Scholar], [Publisher]
- [5] A.R. Noviyanti, H. Haryono, R. Pandu, D.R. Eddy, Cangkang telur ayam sebagai sumber kalsium dalam pembuatan hidroksiapatit untuk aplikasi graft tulang, *Chimica et Natura Acta*, **2017**, *5*, 107-111. [Crossref], [Google Scholar], [Publisher]
- [6] Ł.A. Poniatowski, P. Wojdasiewicz, R. Gasik, D. Szukiewicz, Transforming growth factor Beta family: insight into the role of growth factors in regulation of fracture healing biology and potential clinical applications, *Mediators of inflammation*, **2015**, *2015*. [Crossref], [Google Scholar], [Publisher]
- [7] Kementerian Pertanian RI. Livestock and Animal Health Statistics 2023. *Direktorat Jenderal Peternakan dan Kesehatan Hewan*, **2023**. [Publisher]
- [8] G. Ahlborn, B.W. Sheldon, Identifying the components in eggshell membrane responsible for reducing the heat resistance of bacterial pathogens, *Journal of food protection*, **2006**, *69*, 729-738. [Crossref], [Google Scholar], [Publisher]
- [9] M. Šupová, Problem of hydroxyapatite dispersion in polymer matrices: a review, *Journal of Materials Science: Materials in Medicine*, **2009**, *20*, 1201-1213. [Crossref], [Google Scholar], [Publisher]
- [10] A.R. Noviyanti, N. Akbar, Y. Deawati, E.E. Ernawati, Y.T. Malik, R.P. Fauzia, A novel hydrothermal synthesis of nanohydroxyapatite from eggshell-calcium-oxide precursors, *Heliyon*, **2020**, *6*. [Crossref], [Google Scholar], [Publisher]
- [11] Y.M. Sakti, R. Magetsari, Structural evaluation and animal implantation of porous eggshell waster-derived hydroxyapatite graft as bone substitution, *Journal of the Medical Sciences*, **2013**, *45*, 17-26. [Crossref], [Google Scholar], [Publisher]
- [12] T.A. Einhorn, L.C. Gerstenfeld, Fracture healing: mechanisms and interventions, *Nature Reviews Rheumatology*, **2015**, *11*, 45-54. [Crossref], [Google Scholar], [Publisher]
- [13] S. Dahlan, Langkah-langkah membuat proposal penelitian bidang kedokteran dan menerapkan hasil penelitian, **2011**. [Publisher]
- [14] M.V. Enzo, M. Rastrelli, C.R. Rossi, U. Hladnik, D. Segat, The Wnt/ β -catenin pathway in human fibrotic-like diseases and its eligibility as a therapeutic target, *Molecular and cellular therapies*, **2015**, *3*, 1-13. [Crossref], [Google Scholar], [Publisher]
- [15] E.M. Setiawatie, P. Widiyanti, M. Ryan, M. Rubianto, Carbonate hydroxyapatite-hyaluronic acid as bone healing accelerator: In-vitro and in-vivo studies on the alveolar

bone of Wistar rats, *Journal of International Dental and Medical Research*, **2019**, *12*, 1280-1286. [[Google Scholar](#)], [[Publisher](#)]

[16] M. Idulhaq, A. Mudigdo, P. Utomo, B. Wasita, The Evidence-based Effect of Platelet-rich Fibrin in Osteogenesis: A Systematic Review and Meta-analysis, *Open Access Macedonian Journal of Medical Sciences (OAMJMS)*, **2022**, *10*, 66-70. [[Crossref](#)], [[Google Scholar](#)], [[Publisher](#)]

[17] A.A. Alhasyimi, P.S. Pudyani, W. Asmara, I.D. Ana, Effect of carbonated hydroxyapatite incorporated advanced platelet rich fibrin intrasulcular injection on the alkaline phosphatase level during orthodontic relapse, *AIP Conference Proceedings*, AIP Publishing, **2018**. [[Crossref](#)], [[Google Scholar](#)], [[Publisher](#)]

[18] H.A. Varela, J.C. Souza, R.M. Nascimento, R.F. Araújo, R.C. Vasconcelos, R.S. Cavalcante, P.M. Guedes, A.A. Araújo, Injectable platelet rich fibrin: cell content, morphological, and protein characterization, *Clinical oral investigations*, **2019**, *23*, 1309-1318. [[Crossref](#)], [[Google Scholar](#)], [[Publisher](#)]

[19] N.N. Kökdere, T. Baykul, Y. Findik, The use of platelet-rich fibrin (PRF) and PRF-mixed particulated autogenous bone graft in the treatment of bone defects: An experimental and histomorphometrical study, *Dental research journal*, **2015**, *12*, 418. [[Crossref](#)], [[Google Scholar](#)], [[Publisher](#)]

[20] T.C. Dülgeroglu, H. Metineren, Evaluation of the effect of platelet-rich fibrin on long bone healing: an experimental rat model, *Orthopedics*, **2017**, *40*, e479-e484. [[Crossref](#)], [[Google Scholar](#)], [[Publisher](#)]

[21] P. Pripatnanont, T. Nuntanaranont, S. Vongvatcharanon, K. Phurisat, The primacy of

platelet-rich fibrin on bone regeneration of various grafts in rabbit's calvarial defects, *Journal of Cranio-Maxillofacial Surgery*, **2013**, *41*, e191-e200. [[Crossref](#)], [[Google Scholar](#)], [[Publisher](#)]

[22] M. Oliveira, A.d. Silva, S. Ferreira, C. Avelino, I. Garcia Jr, R. Mariano, Influence of the association between platelet-rich fibrin and bovine bone on bone regeneration. A histomorphometric study in the calvaria of rats, *International journal of oral and maxillofacial surgery*, **2015**, *44*, 649-655. [[Crossref](#)], [[Google Scholar](#)], [[Publisher](#)]

[23] A.S. Wardhana, I. Nirwana, H.S. Budi, M.D.C. Surboyo, Role of hydroxyapatite and ellagic acid in the osteogenesis, *European Journal of Dentistry*, **2020**, *15*, 008-012. [[Crossref](#)], [[Google Scholar](#)], [[Publisher](#)]

[24] V. Hruschka, S. Tangl, Y. Ryabenkova, P. Heimel, D. Barnewitz, G. Möbus, C. Keibl, J. Ferguson, P. Quadros, C. Miller, Comparison of nanoparticulate hydroxyapatite pastes of different particle content and size in a novel scapula defect model, *Scientific reports*, **2017**, *7*, 43425. [[Crossref](#)], [[Google Scholar](#)], [[Publisher](#)]

How to cite this article: Mujaddid Idulhaq*, Pamudji Utomo, Ambar Mudigdo, Brian Wasita. Effect of Platelet Rich Fibrin (PRF) and hydroxyapatite from eggshells to TGF β and ALP in the healing of rat bone defects. *Eurasian Chemical Communications*, 2024, 6(5), 492-501. **Link:** https://www.echemcom.com/article_186320.html